

1. Category: Case series
2. Institution information a. Tampa General Hospital Cancer Institute, Tampa, Florida  
b. Ambry Genetics, Aliso Viejo, California  
c. Mayo Clinic Florida, Department of Clinical Genomics, Jacksonville, Florida
3. Author information a. Brittany Faye Sears, PhD, MSPH, LCGC  
b. Colin C. Young, PhD  
c. Douglas Riegert-Johnson, MD
4. Presenting author: Brittany Sears, bsears@tgh.org
5. Abstract title a. A novel insertion/deletion in *APC* gene Promotor 1B is associated with both stomach and colon polyposis

Background and Aim: Pathogenic variants in *APC* gene promoter 1B are associated with gastric adenocarcinoma and proximal polyposis of the stomach (GAPPS). Here, we present a multi-clinic and laboratory identification of a previously undescribed *APC* promoter 1B insertion/deletion, which appears to cause an autosomal dominant GAPPS presentation as well as colon polyposis. This case series elucidates the potential spectrum of cancer risks for individuals affected by this and similar *APC* promoter 1B variants.

Clinical Presentation: The family proband is a female of unspecified white ancestry. She was diagnosed with gastric polyposis and adenocarcinoma at age 39 and had a curative gastrectomy. She is now 60 with a reported cumulative history of between 50 to 100 colon adenomas. Multi-gene panel testing in 2022 identified an insertion/deletion within *APC* promoter 1B: *APC* c.-192\_-191delATinsTAGCAAGGG (NM\_001127511).

Discussion: We present a four-generation pedigree, Figure 1. Ages of gastric cancer presentation in the family range from 39-60's, with prophylactic gastrectomies at ages 11 and 13 in the proband's daughter and nephew. Six of the 12 affected relatives have undergone gastrectomy; four had colectomies due to colon polyposis. The youngest known carrier in the family is a 10-year-old female, and the oldest living presumed carrier is the proband's brother, 66.

Conclusion: This novel indel is suggestive of a joint GAPPS and FAP presentation in a previously unreported large kindred. Although the mechanism for this mixed phenotype is unclear, it suggests there may be previously uncharacterized genotype-phenotype correlations for *APC* promoter 1B variants. Patients with this and similar *APC* variants should therefore be evaluated for both stomach and colon polyps for cancer risk management until clearer risk estimates are available. We hereby confirm that the consent of the relevant patient(s) has been obtained to submit this Case Reports / Case Series abstract.

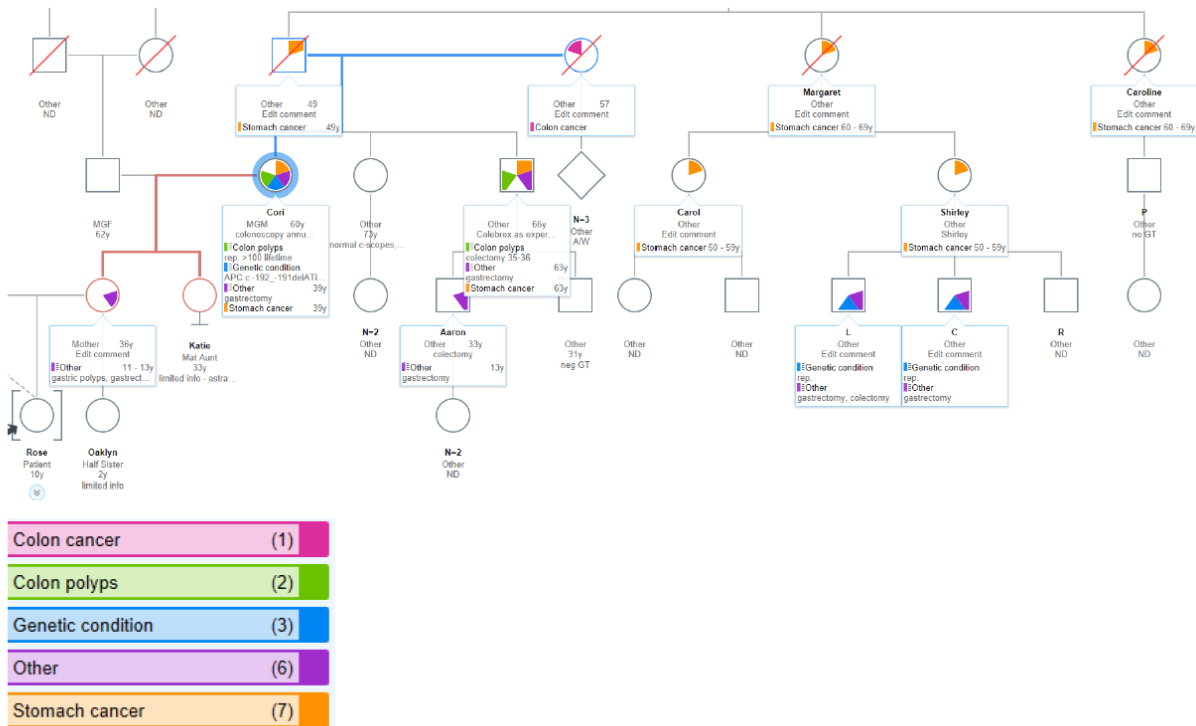
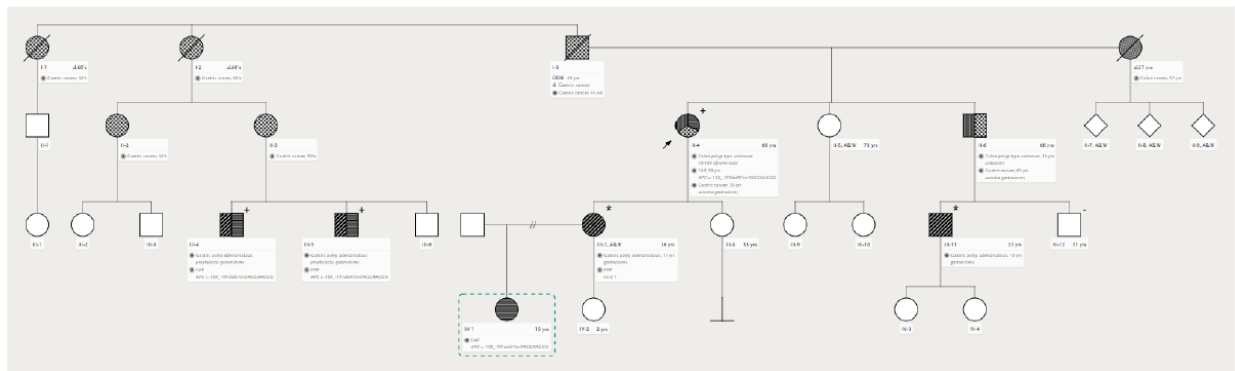


Fig 1. Four-generation kindred affected by APC c.-192\_-191delATinsTAGCAAGGG likely pathogenic variant.



- LEGEND
- Colon polyp type unknown
  - FAP
  - Gastric cancer
  - Colon cancer
  - Gastric polyp adenomatous

Fig 1. Four-generation kindred affected by APC c.-192\_-191delATinsTAGCAAGGG; +: positive molecular testing for APC c.-192\_-191delATinsTAGCAAGGG; -: negative genetic testing; \*: untested obligate carrier; \* prophylactic gastrectomy due to gastric polyposis. Unless otherwise noted, no information is available for other family members listed.